

Expression of Alpha - Methylacyl - Coenzyme A Racemase (AMACR) in Colorectal Neoplasia

NIDHI SHUKLA¹, AMIT KUMAR ADHYA², JAYSREE RATH³

ABSTRACT

Introduction: Red meat and dairy products have been implicated in colonic cancers. They are rich in branched chain fatty acids which require an enzyme Alpha-Methylacyl-Coenzyme A Racemase (AMACR) for their oxidation. Increased expression of AMACR in colorectal premalignant lesions and carcinomas suggests its possible role in carcinogenesis.

Aim: To study the expression of AMACR in colorectal neoplasia and its correlation with the histological grade, stage and nodal status of colorectal malignancy.

Materials and Methods: All cases of colorectal neoplasms were included in the study. AMACR expression was studied in 56 cases which included 44 cases of adenocarcinoma and 12 cases of adenoma and a normal colonic mucosal tissue was used as a control. A tissue microarray was prepared by manual method. AMACR expression was studied by Immunohistochemistry (IHC) and it was correlated with the grade, stage and nodal status of the cancer. Chi-square test was used for analysis of results. The p-value of <0.05 was considered significant.

Results: Out of 12 cases of adenoma 25% (3/12) were negative; 50% (6/12) showed poor expression, 25% (3/12) had moderate expression and none showed strong expression. Nearly, 34.1% (15/44) case of carcinoma were negative; 45.45% (20/44) had poor; 13.63% (6/44) had moderate and 6.81% (3/44) had a strong expression. Normal colonic tissue showed no expression. There was no significant difference of AMACR expression between adenoma and carcinoma cases. AMACR expression was found to be increased in low grade carcinomas (G1 and G2). G1 showed AMACR positivity in 62% cases and G2 showed 71.4% positivity. No association was found between AMACR expression and different American Joint Committee on Cancer (AJCC) stages and nodal status of CRC.

Conclusion: Increased expression of AMACR in adenomas and carcinomas as compared to non-neoplastic epithelium of colon implies that, it plays a role in colorectal neoplasia. Decreased expression of AMACR in high grade carcinomas suggests its role in differentiation of the tumour.

Keywords: Adenomas, Colorectal cancer, Tissue microarray

INTRODUCTION

Colorectal cancer is the third most common cancer in men and second most common cancer in women, worldwide [1]. Increased risk of colon cancer has been linked with ingestion of red meat, processed meat and low vegetable and fibre consumption. Red meat and dairy products are rich in branched chain fatty acids which require an enzyme AMACR/P504S for their oxidation. It is an enzyme bimodally located in mitochondria and peroxisomes; required in β -oxidation of branched chain fatty acids [2]. Increased AMACR expression is seen in many premalignant conditions and various carcinomas such as prostatic adenocarcinoma, colorectal carcinoma, hepatocellular carcinoma and renal cell carcinoma [3-6]. Increased expression of AMACR in colorectal premalignant lesions and carcinomas suggests that it has a possible role in colorectal carcinogenesis [7].

It is possible that AMACR induced by dietary factors plays a role in regulating cell proliferation as overexpression of acyl-CoA oxidase, regulated by AMACR, can transform cells in vitro. Also, it has been found that overexpression of AMACR by transfection of plasmid cDNA expressing the full-length gene results in increased overall proliferation rate of prostate tumour cells [7]. Another hypothesis says that overexpression of AMACR in the development of cancer may play a role in providing energy for the neoplastic cells [8].

The aim of the study was, to study the expression of AMACR in colorectal neoplasia and its correlation to histological grade and stage of the colorectal malignancy. The study is clinically relevant as AMACR may be used as a prognostic marker and may have a possible role in targeted therapy of the disease.

MATERIALS AND METHODS

This prospective study was conducted in the Department of Pathology, Kalinga Institute of Medical Sciences, Bhubaneswar, Odisha, India, from September 2013 to August 2015. The research was done after obtaining clearance from the Ethical Committee of the Institution. The procedures followed were in accordance with the ethical standards of the responsible committee on human experimentation (institutional or regional) and with the Helsinki Declaration of 1975 that was revised in 2000.

A total of 56 cases were analysed in the study, which included 44 cases of adenocarcinoma and 12 cases of adenoma. The age of patients ranged from 21-83 years with a male to female ratio of 2:1. A tissue microarray was prepared by manual method.

Preparation of tissue microarray: Tissue blocks were taken and fresh full face 3 μ m HandE sections were cut and reviewed under the light microscope. The area of interest was identified and marked on the glass slide. Corresponding area on the tissue block was matched and marked. A bone marrow trephine biopsy needle was used to punch out tissue cores from the donor blocks. For this, the stylet was removed from the cannula handle and the cannula was inserted within the marked area on the tissue block upto 5 mm depth. Then the cannula was taken out and the stylet was inserted inside the cannula to gently push out the tissue core. On a clean table, an area was marked with 30 dots using a pencil as per the plan of tissue microarray layout. An adhesive transparent tape was applied on the area so that the dots were still visible. Now, one by one the tissue cores were picked by forceps and placed over the dots according to the order of numbering of blocks. The tissue

cores got glued to the adhesive tape. Once all the tissue cores were placed an L-mould was kept over the marked area. Molten wax was gradually poured inside the mould. After the wax solidified, the mould was removed and the block was kept on the cold plate. When the block was ready thin; 3 μ sections were cut and taken on albumin coated slides.

AMACR expression was studied by standard (IHC) methods. IHC evaluation of AMACR was done on formalin fixed paraffin embedded tissue sections (3 μm-4 μm thick) on poly-L lysine coated slides by using polymer two step indirect methods using antibodies and chemicals obtained from Biogenex, USA. (clone-AN538-5M).

Assessment of staining: The assessment of IHC staining was carried out by three independent pathologists. A semi quantitative system based on intensity of reaction product and percentage of cells showing cytoplasmic positivity were used.

Staining intensity was scored as negative (0), weak (1+), moderate (2+), and strong (3+).

The extent of staining was represented as percentages of positive staining areas in relation to the whole carcinoma area. It was scored as 0-5% (Score 0), 6-20% (Score 1), 21-40% (Score 2), 41-60% (Score 3), 61-80% (Score 4), and 81-100% (Score 5) [Table/Fig-1a-d].

The product of intensity and extent of staining scores were used as final staining scores (0-15). For the purpose of statistical analysis, tumours having a final staining score of ≥1 were considered to be positive. The final scores of AMACR expression were graded as negative (Score 0), poor (Score 1-5), moderate (Score 6-10), strong (Score 11-15).

STATISTICAL ANALYSIS

Statistical analysis was done to find out the significance of AMACR expression in adenoma and carcinoma and association between AMACR expression and various histopathological parameters. The relationship between qualitative parameters was determined using the Chi-square test. Statistical significance was defined as p<0.05.

RESULTS

A total of 56 cases were taken including colorectal adenomas, adenocarcinoma and one normal colonic tissue used as control tissue. The age range of patients was 21-83 years with a mean age of 50.51 years (SD=11.12). Out of all cases 21 (47.7%), 21 (47.7%) and 2 (4.5%) were Grade 1, 2 and 3 respectively. A 15.9% (7/44), 40.9% (18/44) and 43.18% (19/44) cases were in Stage I, II and III respectively. Maximum numbers of cases were Stage IIA and only two cases were of Stage IIB. For the purpose of analysis Stage I and II tumours were combined together.

A 56.81% (25/44) cases were node negative (N0) and 43.18% (19/44) cases were node positive (N1 and N2). While doing statistical analysis N1 and N2 were grouped together as node positive cases.

There were 12 (20%) cases of adenoma comprising of 41.66% (5/12) villous adenoma, 33.33% (4/12) tubular adenoma and 25% (3/12) tubulovillous adenoma.

AMACR expression in normal colonic tissue, adenoma and carcinoma: There was no AMACR expression in normal colonic tissue. Out of 12 cases of adenoma 25% (3/12) were negative; 50% (6/12) showed poor expression, 25% (3/12) had moderate expression and none showed strong expression. A total of 34.1% (15/44) cases of carcinoma were negative; 45.45% (20/44) had poor; 13.63% (6/44) had moderate and 6.81% (3/44) had a strong expression. Statistical analysis revealed that there is no significant difference of expression between adenoma and carcinoma cases (p>0.05).

AMACR expression in carcinoma of different grades is shown in [Table/Fig-2]. Statistical analysis revealed that there was no

significant difference of AMACR expression in different grades of the tumour (p>0.05) [Table/Fig-3].

AMACR expression in colorectal carcinoma in different AJCC stages: Strong AMACR expression was noted in significant number of cases in Stage I and II, whereas poor expression was seen in tumours of higher stages [Table/Fig-4].

Stage I and II (without nodal involvement) were considered together while performing the statistical analysis. Stage I and II showed 68% (17/25) AMACR expression. Stage III showed 63.15% (12/19) AMACR expression. We did not find any significant association between AMACR expression and stage (Chi-square=0.1125, p>0.05)

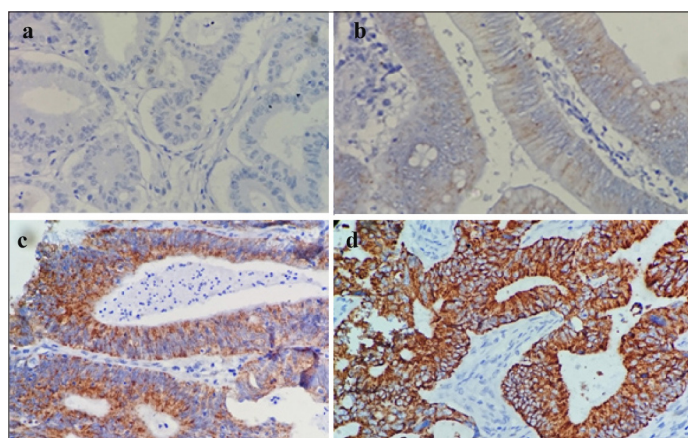
AMACR expression and nodal status: AMACR expression varied according to the nodal metastasis status or the tumours [Table/Fig-5]. There were 68% (17/25) node negative cases showing positive AMACR expression whereas, 63.15% (12/19) node positive cases showed AMACR expression. χ² analysis showed that there is no significant association between AMACR expression and nodal status (Chi-square = 0.1125, p>0.05).

DISCUSSION

AMACR has been found to be up regulated in various carcinomas and their precursor lesions, suggesting a role for this enzyme in the basic mechanism of the early stages of cancer formation [7].

AMACR expression in colorectal adenomas

The present study revealed increased AMACR expression in adenoma cases; with 75% (9/12) cases of adenoma showing positive expression. In the positive cases, there was weak expression in 50% cases and moderate expression in 25% cases. None of the adenoma cases showed strong AMACR expression.



[Table/Fig-1]: Photomicrograph showing different scores of expression of AMACR in colorectal neoplasm, negative a); mild b); moderate c); and strong d).[20X].

Grade	Negative		Poor		Moderate		Strong		Total	
	No.	%	No.	%	No.	%	No.	%	No.	%
G1	8	38.1	7	33.33	3	14.28	3	14.28	21	47.72
G2	6	28.57	12	57.14	3	14.28	0	0	21	47.72
G3	1	50	1	50	0	0	0	0	2	4.545
TOTAL	15	34.1	20	45.45	6	13.63	3	6.81	44	100

[Table/Fig-2]: AMACR expression in carcinoma of different grades.

Grade	Positive		Negative		Total		Chi-square and p-value
	No.	%	No.	%	No.	%	
G1	13	62	8	38	21	50	χ ² = 0.4285 p >0.05
G2	15	71.4	6	28.6	21	50	
TOTAL	28	66.66	14	33.33	42	100	

[Table/Fig-3]: Association between AMACR expression and grade of carcinoma.

Stage	Negative		Poor		Moderate		Strong		Total	
	No.	%	No.	%	No.	%	No.	%	No.	%
I	3	42.85	3	42.85	0	0	1	14.28	7	15.9
IIA	4	26.66	6	40	4	26.7	1	6.66	15	34.1
IIB	1	33.33	0	0	1	33.3	1	33.33	3	6.81
IIIA	1	50	1	50	0	0	0	0	2	4.54
IIIB	2	33.33	4	66.66	0	0	0	0	6	13.6
IIIC	4	36.36	6	54.54	1	9.09	0	0	11	25
TOTAL	15	34.09	20	45.45	6	13.6	3	6.81	44	100

[Table/Fig-4]: AMACR expression in colorectal carcinomas in different AJCC stages.

Stage	Negative		Poor		Moderate		Strong		Total	
	No.	%	No.	%	No.	%	No.	%	No.	%
N0	8	32	9	36	5	20	3	12	25	56.8
N1	3	37.5	5	62.5	0	0	0	0	8	18.2
N2	4	36.36	5	45.45	2	18.2	0	0	11	25
TOTAL	15	34.1	19	43.18	7	15.9	3	6.81	44	100

[Table/Fig-5]: AMACR expression in different nodal stages of colorectal carcinomas.

Authors	AMACR expression in adenomas	AMACR expression in carcinomas	Association with grade	Association of AMACR expression with stage	Association with nodal status
Jiang Z et al., [4]	Increased expression in 79% cases.	Increased expression in 69% cases	Significant association with grade	No correlation with Overall AJCC stage	No correlation with nodal status
Lin A et al., [9]	Increased expression in 64% cases.	Increased expression: Variable positive -75%, Moderate to Strong-39%	Significant correlation with grade	No correlation with AJCC staging	Significant association of AMACR expression and nodal status
Marx A et al., [10]	Adenomas not included in study.	Increased expression in 81.7% cases	Significant association with grade	Decreasing AMACR expression with higher tumour stage	
Present study	Increased expression in 75% cases	Increased expression in 66% cases	No association of expression in G1 and G2	No association with AJCC stage	No association found

[Table/Fig-6]: Table showing the comparison of results obtained by various researchers.

Jiang Z et al., studied AMACR expression in adenomas, carcinomas and hyperplastic polyps [4]. They found positive AMACR expression in 79% (30/38) cases of adenoma. Lakis S et al., had confined their study to expression of AMACR in sporadic colorectal adenomas and they also found an increased expression of AMACR in adenomas associated with a higher grade of dysplasia, larger size and villous configuration [8].

Current study findings were similar to Jiang Z et al., and Lakis S et al., [4,8]. Since adenomas are precursors of colorectal carcinomas and they also show increased expression of AMACR, implies that AMACR plays a role in colorectal carcinogenesis. Also, this suggests possible role of AMACR as a diagnostic marker for neoplastic change.

AMACR expression in carcinomas

There were 44 cases of adenocarcinoma in the present study and 66% showed positive AMACR immunoreactivity. In adenocarcinoma,

6.81% showed a strong reaction for AMACR; 13.63% had moderate expression and 45.45% poor expression and 34.1% (15/44) showed no expression.

Overexpression of AMACR in colorectal carcinomas was reported by many workers. Studies by Jiang Z et al., showed increased expression in 69% (122/176) cases of colorectal carcinomas [4]. Shi X et al., found AMACR positivity in 59.4% (63/106) cases [7]. Lin A et al., performed their study on a tissue microarray with variable positive staining in 75% (123/163) cases and moderate to strong staining in 39% (63/163) cases [9]. Marx A et al., also performed their study on a tissue microarray but containing a much larger sample (1,315 cases of colorectal carcinomas) [10] compared to the study by Lin A et al., (163 cases of colorectal carcinomas) [9]. Findings of the present study corroborated with the previous works that expression of AMACR increases in carcinoma cases [Table/Fig-6].

None of the previous studies have compared the expression of AMACR in adenoma with carcinoma. In the present study, a comparison was made between AMACR expressions in adenoma (75% AMACR positivity) versus carcinoma cases (69% AMACR positivity). There was no significant difference of AMACR expression between adenoma and carcinoma cases. Therefore, AMACR cannot be used to distinguish between adenoma and carcinoma cases.

Association between AMACR expression and grades of adenocarcinoma

It has been found in previous studies that AMACR expression varies with the degree of differentiation of tumour. There is no or very low AMACR expression in cases of normal colon; significant up regulation in cases of adenomas as well as moderately differentiated adenocarcinoma. There is low expression in cases of poorly differentiated or undifferentiated carcinoma. Thus, AMACR expression is significantly associated with tumour differentiation and has a possible role in colorectal carcinogenesis. It has been hypothesized that overexpression of AMACR in the development of cancer may play an important role in providing energy for the neoplastic cells. In this hypothesis, as the tumours dedifferentiate, they take over other pathways to accomplish the same supply of energy as branched chain fatty acid oxidation. This phenomenon raises the possibility that during the progression of some carcinomas, a genetic abnormality may occur in a sub clone of cancer cells which eliminates the requirement for AMACR, although more direct evidence should be found to verify this [8].

Present study compared AMACR expression in Grade I-62% (13/21) cases and Grade II-71.4% (15/21) cases of adenocarcinoma to find out if there is any significant association between AMACR expression and grade of carcinoma. There were only two cases of Grade III (high grade) so they were not included in this analysis as such a small number is statistically insignificant.

In the study by Lin A et al., there was variable to strong positivity in 39% (63/163) cases and variable positivity in 75% (123/163) cases [9]. There was lack of staining in poorly differentiated carcinoma. They found significant correlation of AMACR expression with the grade of carcinoma. Marx A et al., also concluded that AMACR expression is significantly associated with grade of carcinoma [10].

Jiang Z et al., had 76% and 75% AMACR positivity in well and moderately differentiated cases [4]. This study also had comparable findings with 62% positivity in well differentiated and 71.4% in moderately differentiated. The difference was that they had 36% positivity in poorly differentiated cases and Grade III cases were not included in this analysis. Similarly Shi X et al., had compared well and moderately differentiated cases with poorly differentiated cases and got a significant difference of AMACR expression between the two groups [7].

Current study had only two cases of Grade III out of which one was negative and the other showed weak immunoreactivity for AMACR.

The normal colonic tissue which were included as control tissue and also the normal colonic mucosa adjacent to the tumour showed weak or no positivity.

Association between AMACR expression and AJCC staging of colorectal carcinoma

Stage I and II had 68% (17/25) cases positive for AMACR and stage III had 63.15% (12/19) AMACR positivity. No significant association was found between AMACR expression and AJCC stage of colorectal carcinoma. The results of this study were similar to Jiang Z et al., and Lin A et al., [4,9]. Jiang Z et al., had found no correlation between AMACR expression and TNM staging or overall stage [4]. Lin A et al., did not find any correlation between AMACR expression and AJCC staging [9]. Marx A et al., had concluded that AMACR expression was significantly associated with tumour stage [10].

Association between AMACR expression and nodal status

No significant difference of AMACR expression was found between the node positive and node negative colorectal carcinomas. Present study results were similar to Jiang Z et al., who did not find any correlation between AMACR expression and nodal status [4]. On the contrary Lin A et al., found significant association between AMACR expression and nodal status [9]. They had 59% N0 cases showing low AMACR expression and 41% cases showing strong expression. In node positive group (N1 and N2) 65% low expression and 35% strong expression was seen.

LIMITATION

The major limitation of the current study is small sample size. Follow up of the cases is also necessary for correlating AMACR expression with disease free survival. Further, only one case of normal colonic mucosa was taken as control. A larger number of controls would be necessary to validate the findings.

CONCLUSION

This study shows an increased expression of AMACR in colorectal adenomas and carcinomas as compared to normal colonic epithelium thereby, suggesting a possible role of AMACR in colorectal carcinogenesis. However, it cannot be used to distinguish

between adenomas and carcinomas. AMACR expression was not associated with tumour stage or nodal status. Further studies are required in this regard to establish AMACR as a prognostic marker in colorectal neoplasia and to find out its possible role in targeted therapy of the disease.

ACKNOWLEDGEMENTS

The statistical help provided by Dr. Ansuman Panigrahi is acknowledged. Technical help provided by Mr. Nishkar Sahoo for the preparation of tissue microarray is acknowledged.

REFERENCES

- [1] Ferlay J, Soerjomataram I, Dikshit R, Eser S, Mathers C, Rebelo M, et al. Cancer incidence and mortality worldwide: Sources, methods and major patterns in GLOBOCAN 2012. *Int J Cancer*. 2015;136:359-86.
- [2] Ferdinandusse S, Denis S, IJlst L, Dacremont G, Waterham HR, Wanders RJ. Subcellular localization and physiological role of α -methylacyl-CoA racemase. *J Lipid Res*. 2000;41:1890-96.
- [3] Rubin MA, Zhou M, Dhanasekaran SM, Varambally S, Barrette TR, Sanda MG, et al. α -Methylacyl coenzyme a racemase as a tissue biomarker for prostate cancer. *JAMA*. 2002;287:1662-70.
- [4] Jiang Z, Fanger GR, Banner BF, Woda BA, Algate P, Dresser K, et al. A dietary enzyme: alpha-methylacyl-CoA racemase/P504S is overexpressed in colon carcinoma. *Cancer Detect Prev*. 2003;27:422-26.
- [5] Xu B, Cai Z, Zeng Y, Chen L, Du X, Huang A, et al. α -Methylacyl-CoA racemase (AMACR) serves as a prognostic biomarker for the early recurrence/metastasis of HCC. *J Clin Pathol*. 2014;67:974-79.
- [6] Molinié V, Balaton A, Rotman S, Mansouri D, De Pinieux I, Homsy T, et al. Alpha-methyl CoA racemase expression in renal cell carcinomas. *Hum Pathol*. 2006;37:698-703.
- [7] Shi X, Gong E, Wu X. Alpha-methylacyl-CoA racemase/P504S overexpression in colorectal carcinoma is correlated with tumour differentiation. *Appl Immunohistochem Mol Morphol*. 2007;15:175-80.
- [8] Lakis S, Papamitsou T, Panagiotopoulou C, Kotakidou R, Kotoula V. AMACR is associated with advanced pathologic risk factors in sporadic colorectal adenomas. *World J Gastroenterol*. 2010;16:2476-83.
- [9] Lin A, Weiser MR, Klimstra DS, Paty PB, Tang LH, Al-Ahmadie H, et al. Differential expression of α -methylacyl-coenzyme A racemase in colorectal carcinoma bears clinical and pathologic significance. *Hum Pathol*. 2007;38:850-56.
- [10] Marx A, Simon P, Simon R, Mirlacher M, Izbicki JR, Yekebas E, et al. AMACR expression in colorectal cancer is associated with left-sided tumour localization. *Virchows Arch*. 2008;453:243-48.

PARTICULARS OF CONTRIBUTORS:

1. Postgraduate Student, Department of Pathology, Kalinga Institute of Medical Sciences, Bhubaneswar, Odisha, India.
2. Associate Professor, Department of Pathology, Kalinga Institute of Medical Sciences, Bhubaneswar, Odisha, India.
3. Professor, Department of Pathology, Kalinga Institute of Medical Sciences, Bhubaneswar, Odisha, India.

NAME, ADDRESS, E-MAIL ID OF THE CORRESPONDING AUTHOR:

Dr. Amit Kumar Adhya,
Associate Professor, Department of Pathology, Kalinga Institute of Medical Sciences,
KIIT, Bhubaneswar-751024, Odisha, India.
E-mail: amitadhya2003@yahoo.com

FINANCIAL OR OTHER COMPETING INTERESTS: None.

Date of Submission: **Nov 09, 2016**
Date of Peer Review: **Dec 19, 2016**
Date of Acceptance: **Feb 09, 2017**
Date of Publishing: **Apr 01, 2017**